Updates in Breast Imaging
Early Detection
Artificial Intelligence

Juliette The, MD

Department of Radiology

Baptist Health South Florida

US Breast Cancer Statistics

- 1 in 8 women (12%) will develop breast cancer over her lifetime
- In 2020, estimated 276,480 cases of invasive breast cancer, 48,530 noninvasive breast cancer
- 2020: 2620 breast cancer cases in men
- Besides skin cancer, most commonly diagnosed cancer in American women
- In women under 45, breast cancer is more common in Black women than white women.
  Overall, black women are more likely to die of breast cancer.
- Ashkenazi Jewish women have a higher risk of breast cancer because of a higher rate of BRCA mutations

Artificial Intelligence Definition

- Intelligence demonstrated by machines
- Attempts to mimic the cognitive function of the human mind
- Technology that hasn’t been achieved yet.

Artificial Intelligence

- In the last 75 years, powerful computers have compressed the time to analyze large amounts of data (images, text)
- 2019, President Trump signed an executive order, **Artificial Intelligence Initiative**
  - Promotes and protects national AI technology
  - Ensures funding
  - Collaborates with private sector, academia and the public

“AI will make jobs kind of pointless,”

Elon Musk said Thursday, speaking alongside Alibaba’s founder Jack Ma at the World Artificial Intelligence Conference in Shanghai.

Artificial Intelligence in Breast Imaging

- Breast Cancer Detection via imaging
- Clinical Efficiency
- Patient risk stratification

How does AI work in breast imaging?

- AI attempts to learn and problem solve like the human mind.
- **Machine Learning (ML):** computer learns from the large amount of pixel data (mammograms) without being programmed. Some data not perceived by experts
- **Deep learning (DL):** subtype of ML.
  - Processes data through multiple layers of **neural network algorithms**, to extract higher level features from raw data
  - Including lines, edges textures, shapes, and lesions.
  - Machines can recognize patterns beyond human recognition.

Figure 2. Structure of a **neural network**. A neural network is composed of groups of nodes with consecutive layers—an input layer, one or more hidden layers, and an output layer.

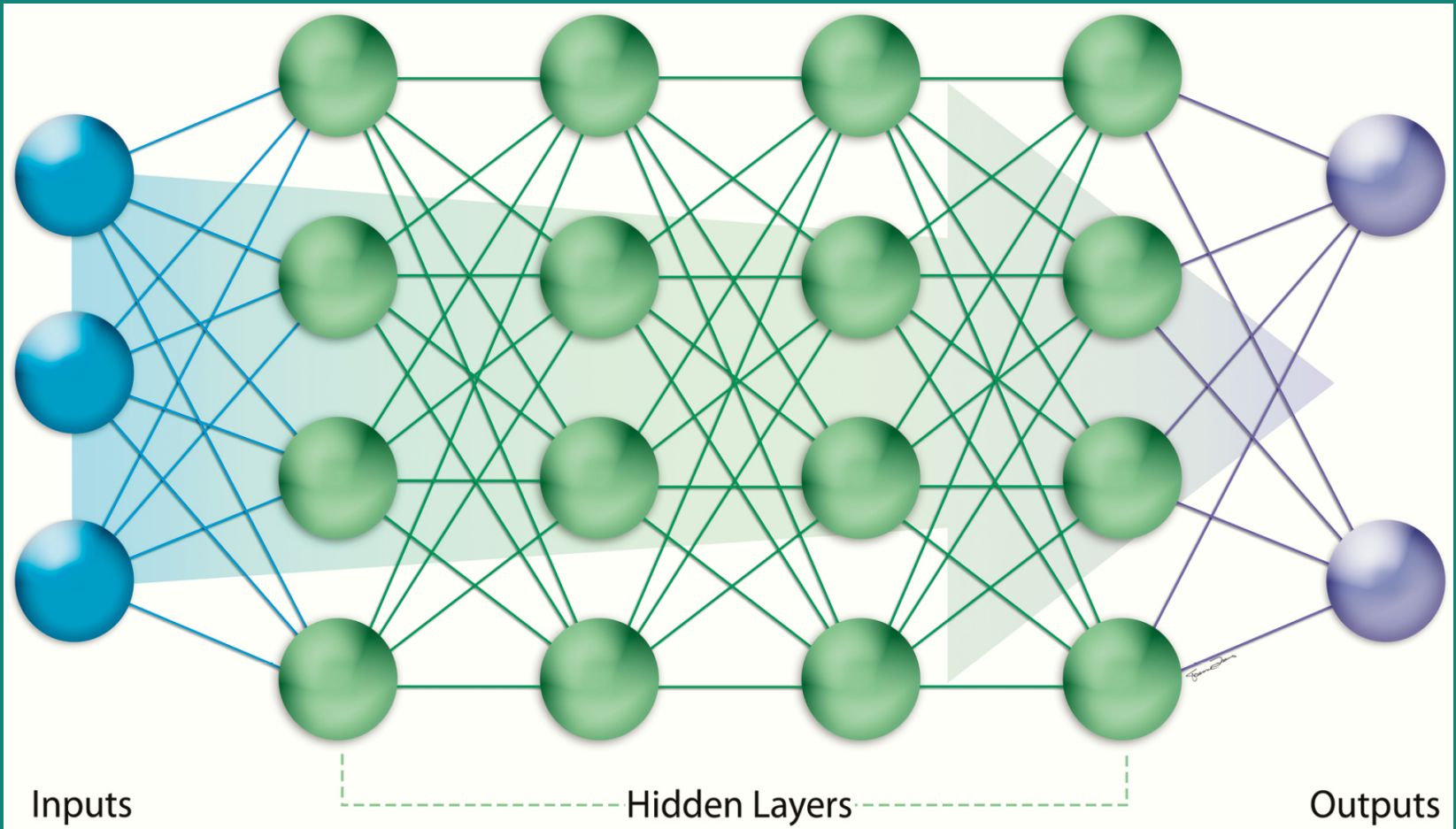

J Breast Imaging, Volume 2, Issue 4, July/August 2020, Pages 304–314,
https://doi.org/10.1093/jbi/wbaa033

Artificial Intelligence in Breast Imaging

- Breast Cancer Detection
- Clinical Efficiency
- Patient Risk Stratification and decision making

Artificial Intelligence Breast Cancer Detection CAD vs AI

- Traditional CAD for 2D images
  - Marks features suspicious for breast cancer based on
  - Human input for detection of suspicious lesions: calcifications, distortion, mass
  - **Equivocal** performance with CAD: Although early findings were promising in smaller retrospective series and reader studies, benefits were not reproduced in larger population-based clinical trials once CAD was widely implemented
    Gao 2019 https://www.ajronline.org/doi/full/10.2214/AJR.18.20392
- AI extract imaging features visible or invisible to the human eye based on Deep Learning

Figure 3. Comparison of traditional ML and DL (3,36). Most published models in the breast imaging literature utilize ...

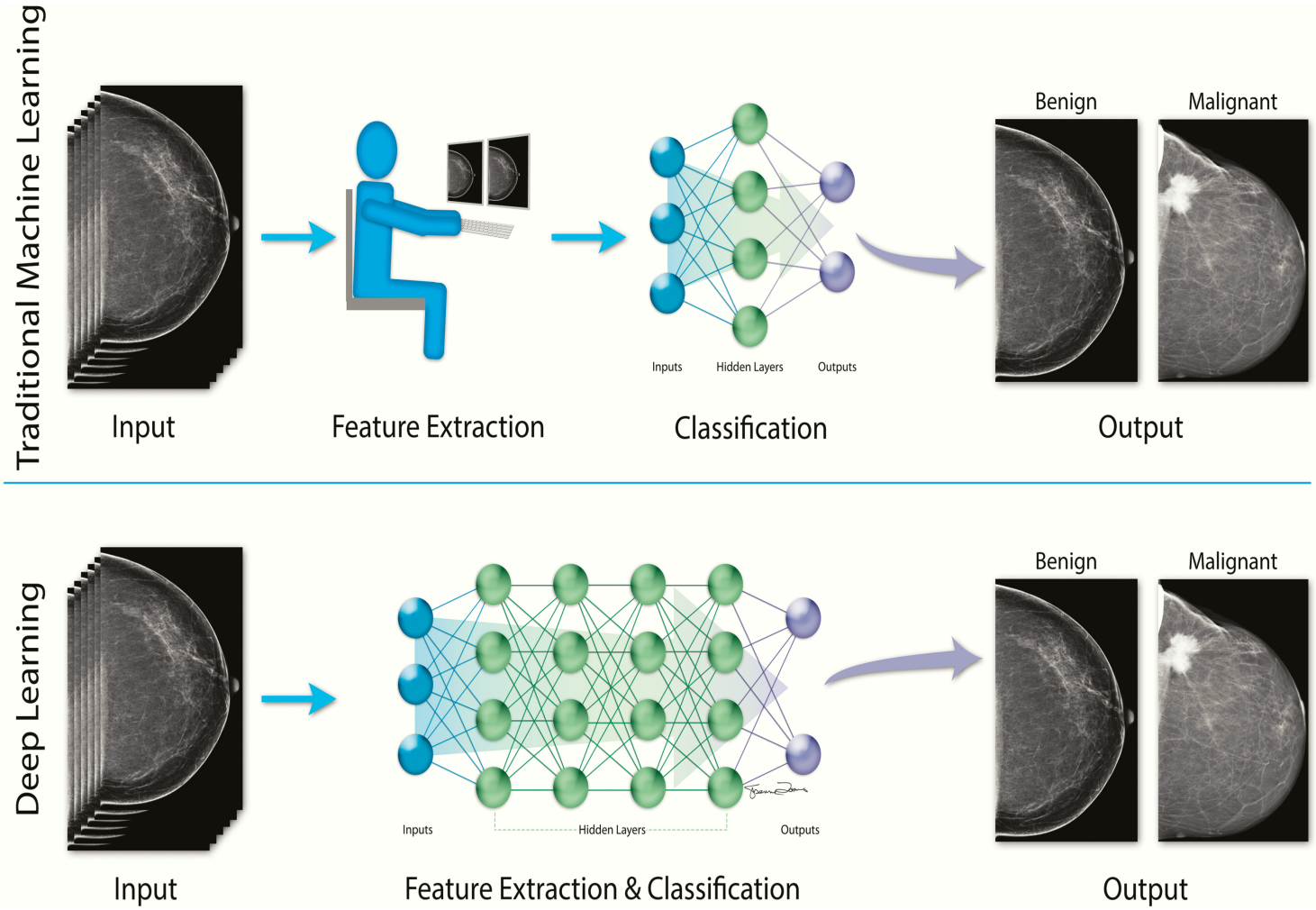

J Breast Imaging, Volume 2, Issue 4, July/August 2020, Pages 304–314, https://doi.org/10.1093/jbi/wbaa033

ProFound AI Example Cases

Case 1: 57-yo for screening in combo DM/DBT mode

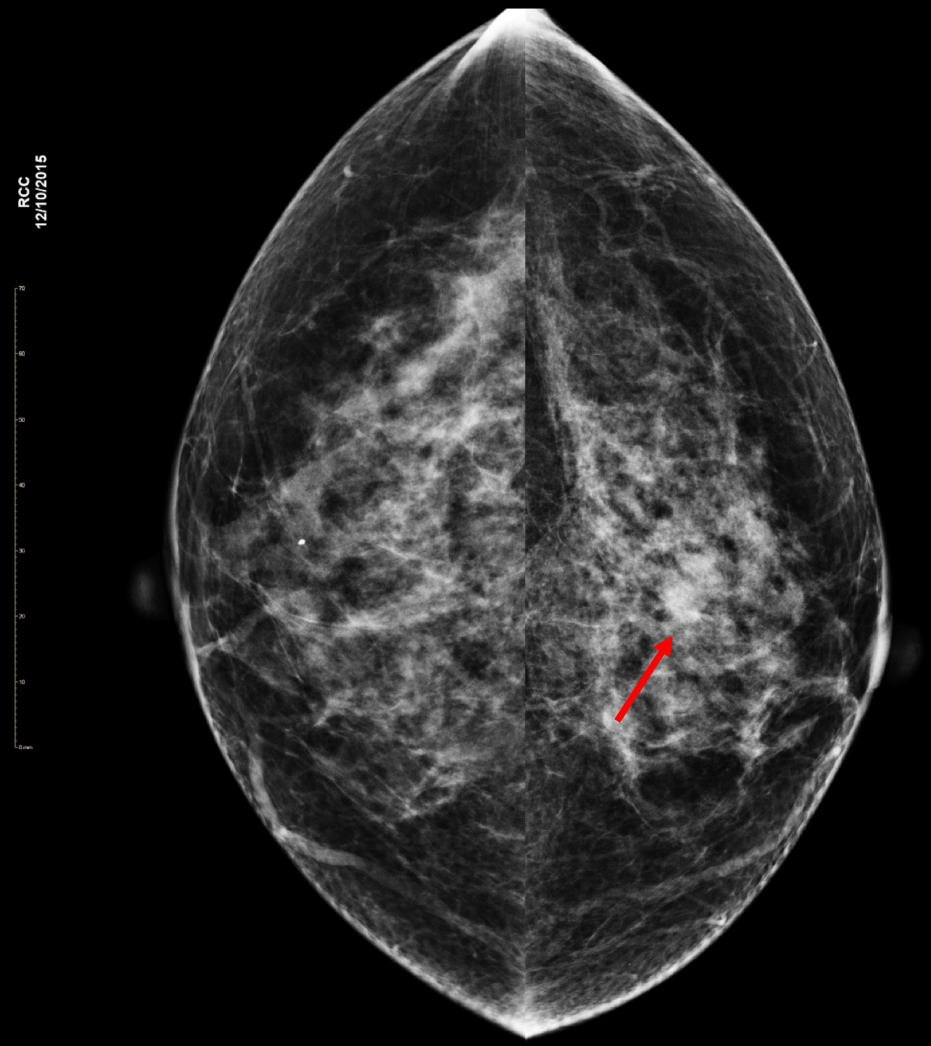

<u>DM views</u>: Dense breasts (d) with Ill-defined mass in central left breast on LCC

Case 1: 57-yo for screening in combo DM/DBT mode

<u>Left DBT slices</u>:

Architectural distortion in central left breast better seen on CC DBT view

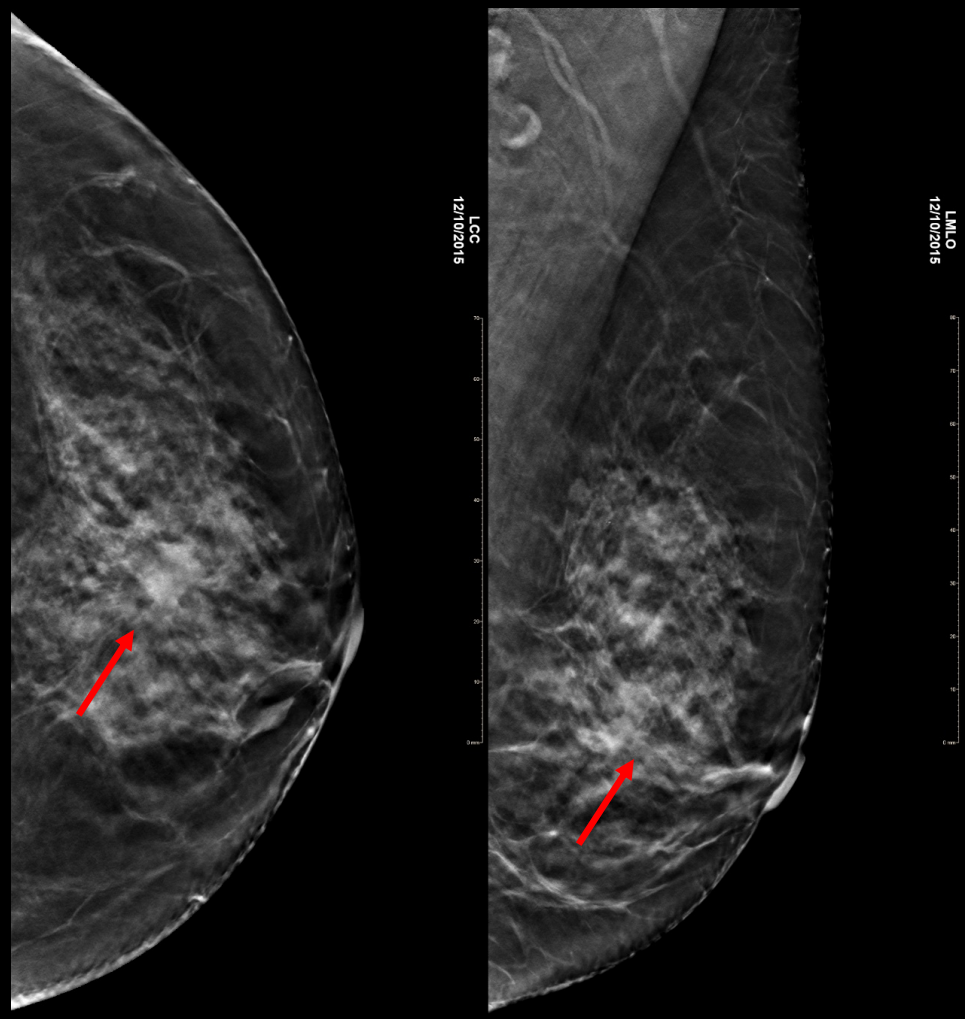

Case 1: Zoomed Lt DBT slices and histopathology

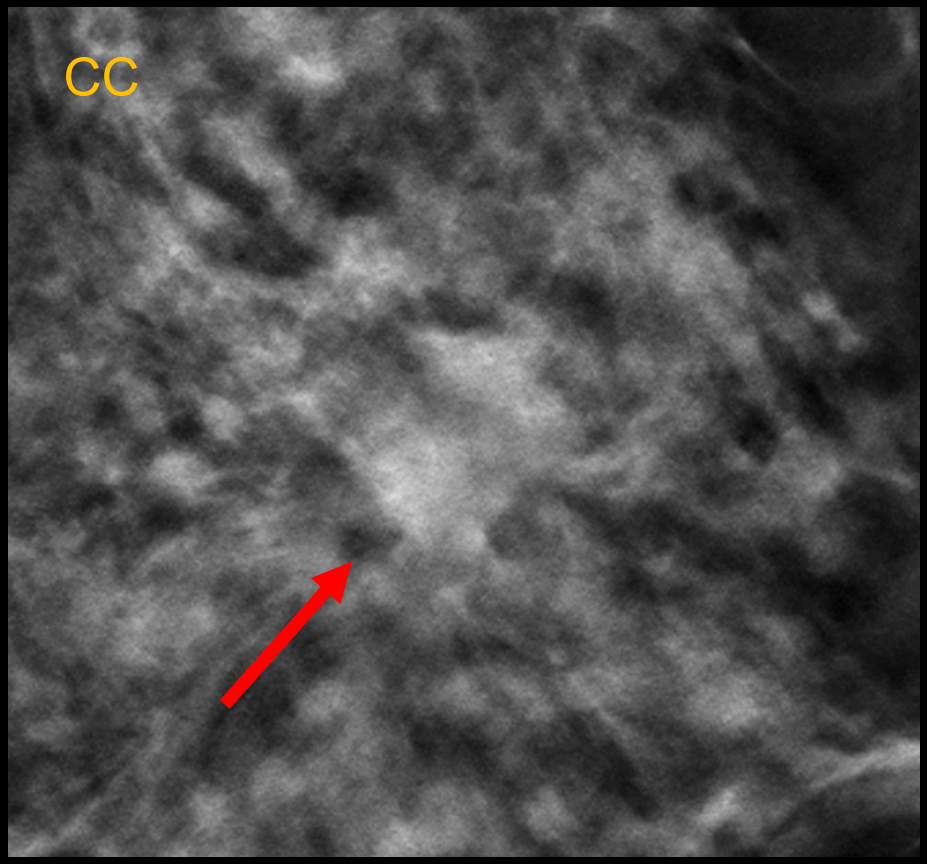

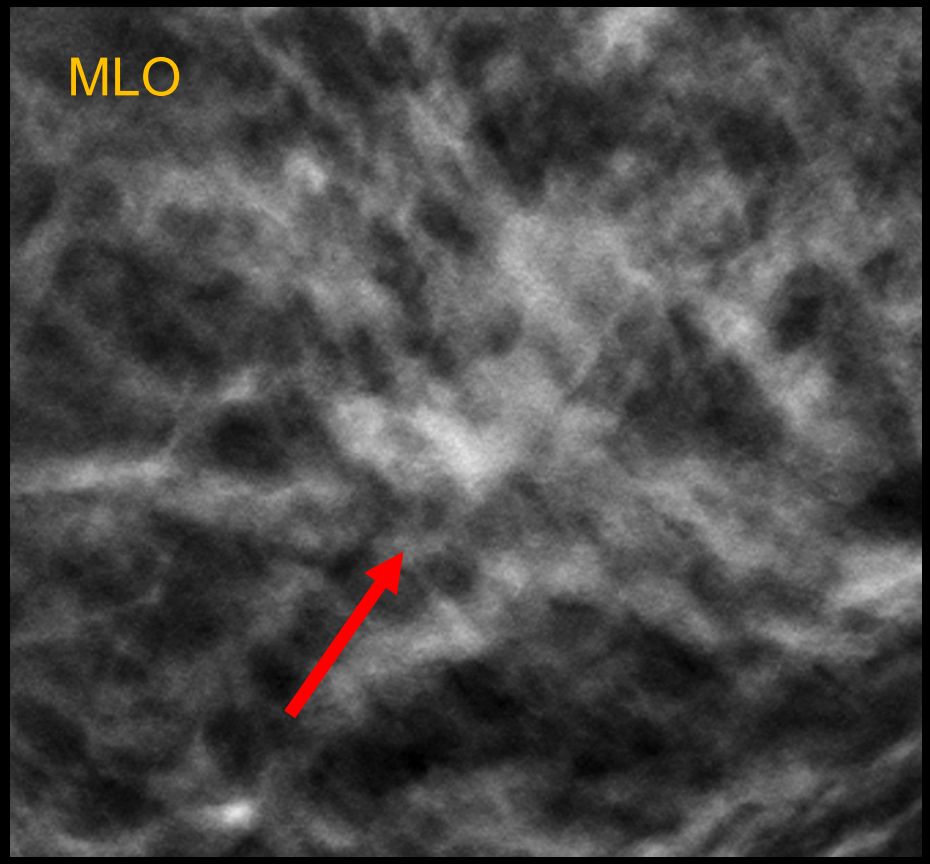

1.4-cm grade 2 invasive ductal carcinoma (ER+, PR+, HER2-, high Ki67)

Case 1: Zoomed Lt DBT slices and histopathology

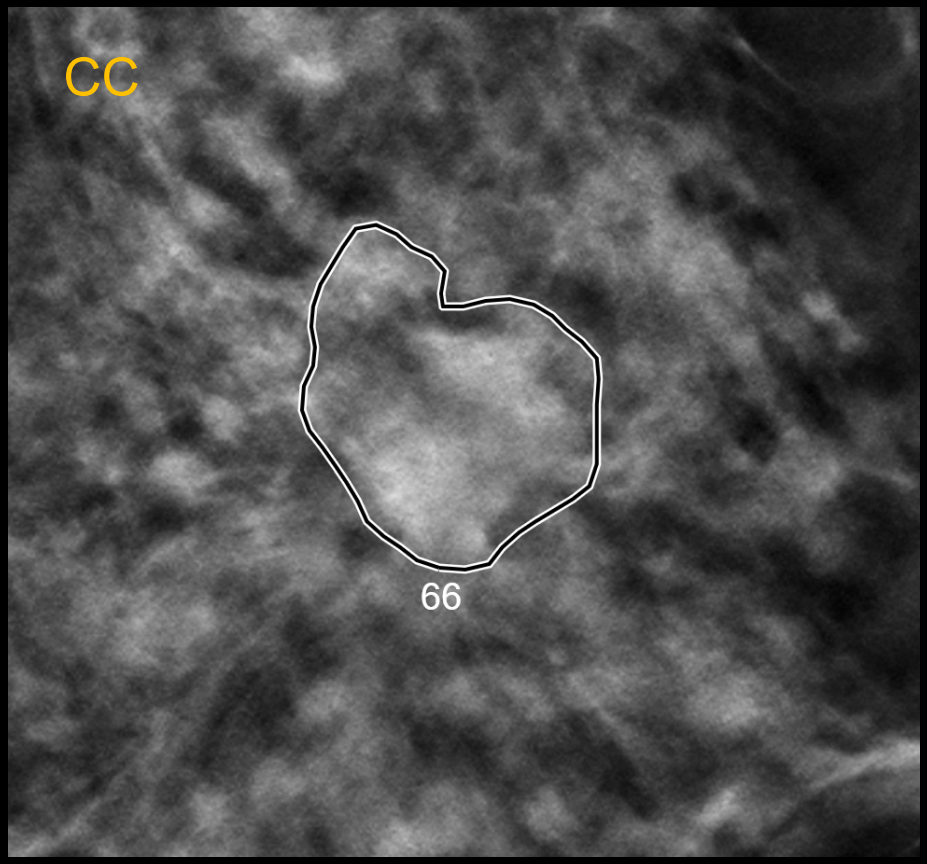

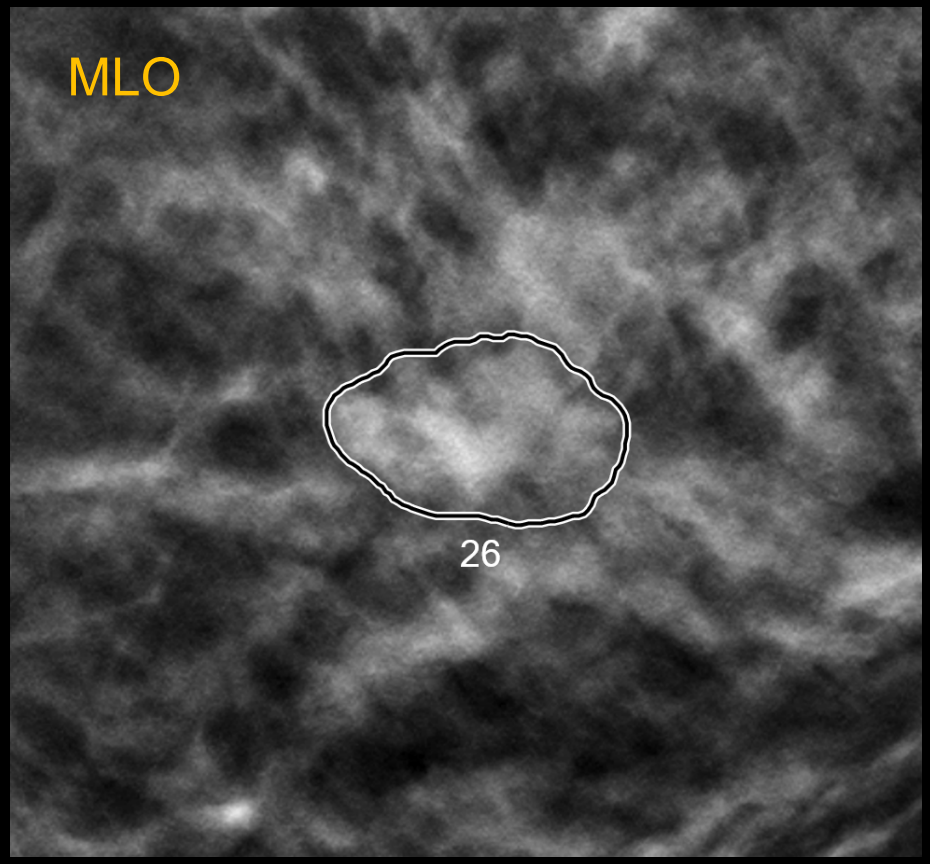

Case Score 84%

1.4-cm grade 2 invasive ductal carcinoma (ER+, PR+, HER2-, high Ki67)

Case 1: Lt DBT slices with ProFound AI outlines and scores

Architectural distortion in dense breasts detected by ProFound AI on both views

CC lesion score: 66%
MLO lesion score: 26%
Case score: 84%

<u>without AI</u>: 12 of 24 readers detected cancer
(average time*: 72.7 sec)

<u>with AI</u>: 22 of 24 (<u>10 more</u>) readers detected cancer
(average time*: 45.6 sec)

Increased sensitivity with use of AI

* Average reading times are for all 24 readers

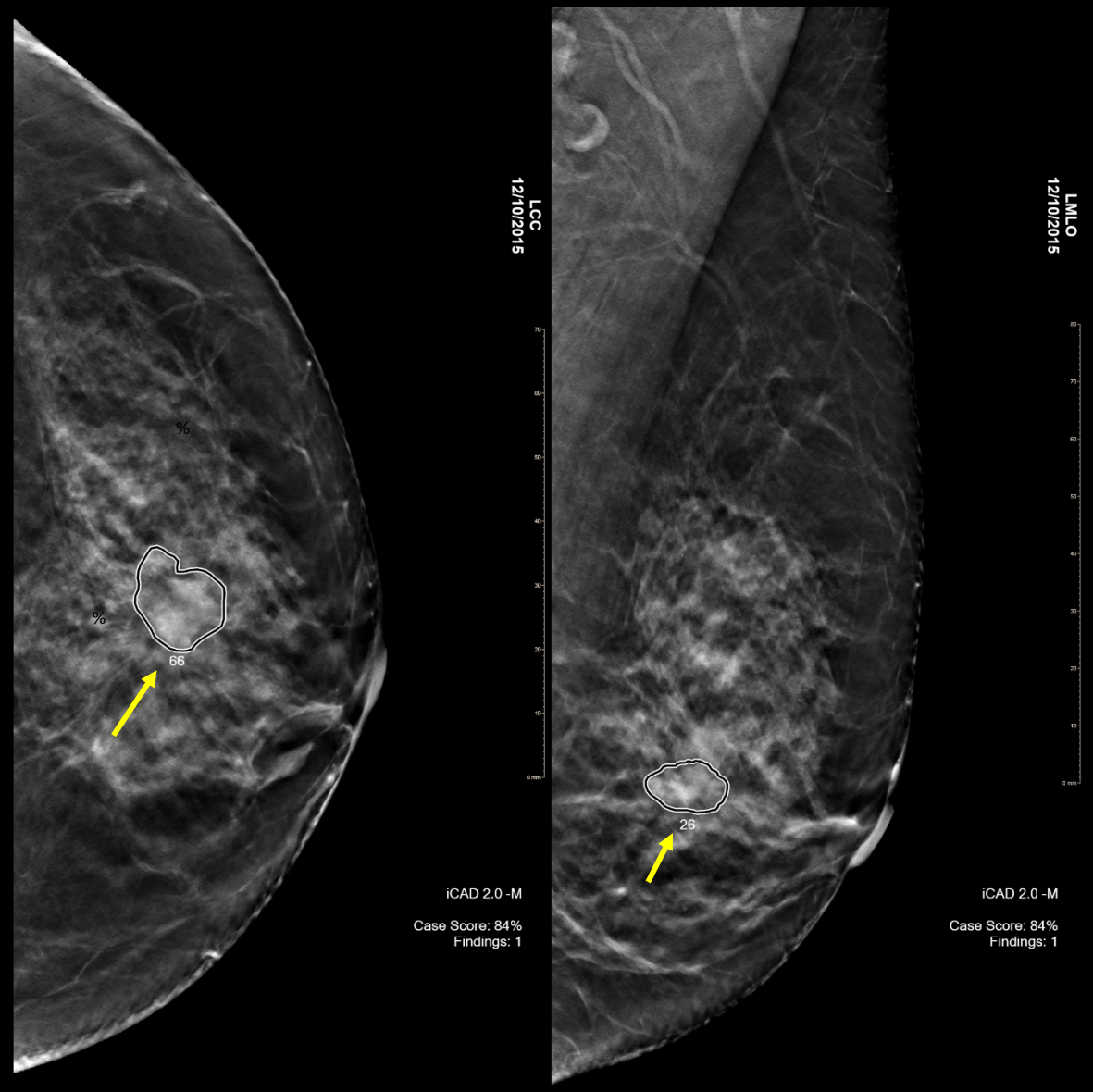

Case 2: 44-yo for screening in combo DM/DBT mode

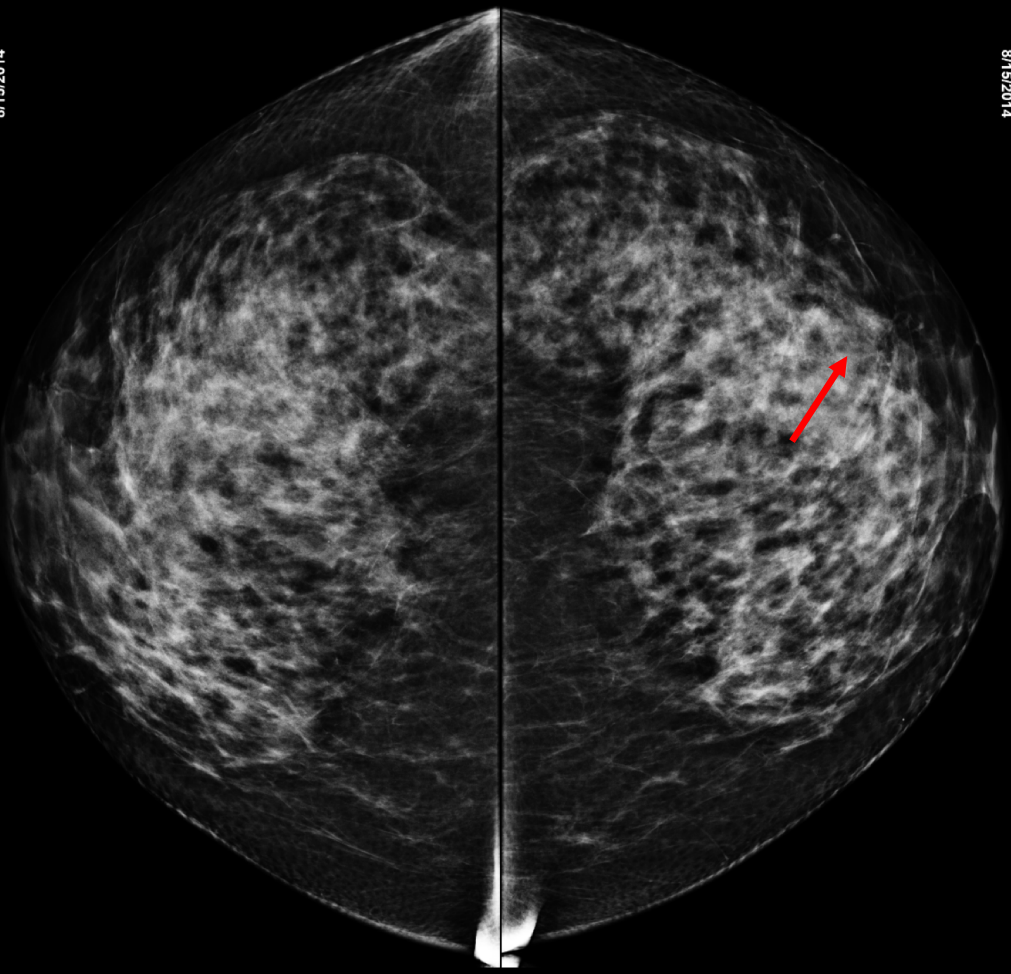

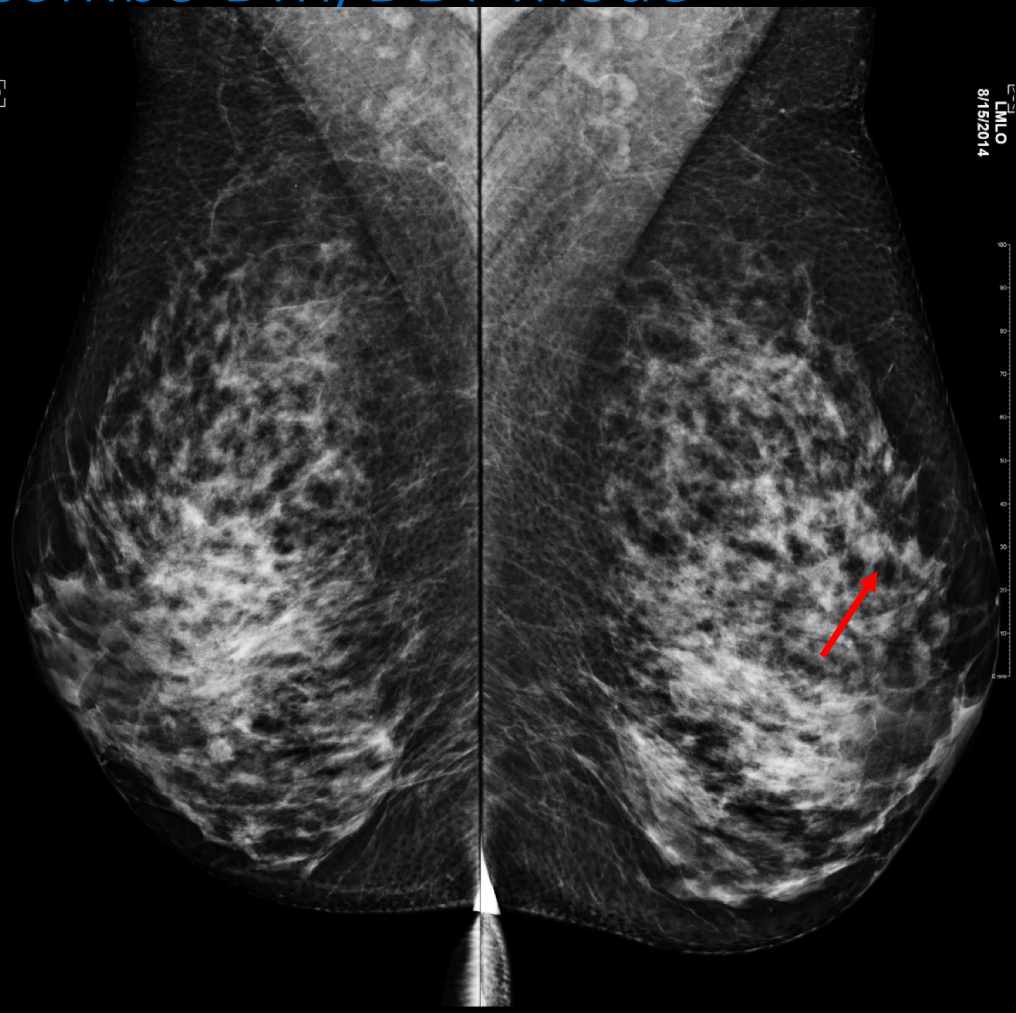

<u>DM views</u>: Dense breasts (c) with grouped calcifications in left OUQ

Case 2: Zoomed Lt DM views

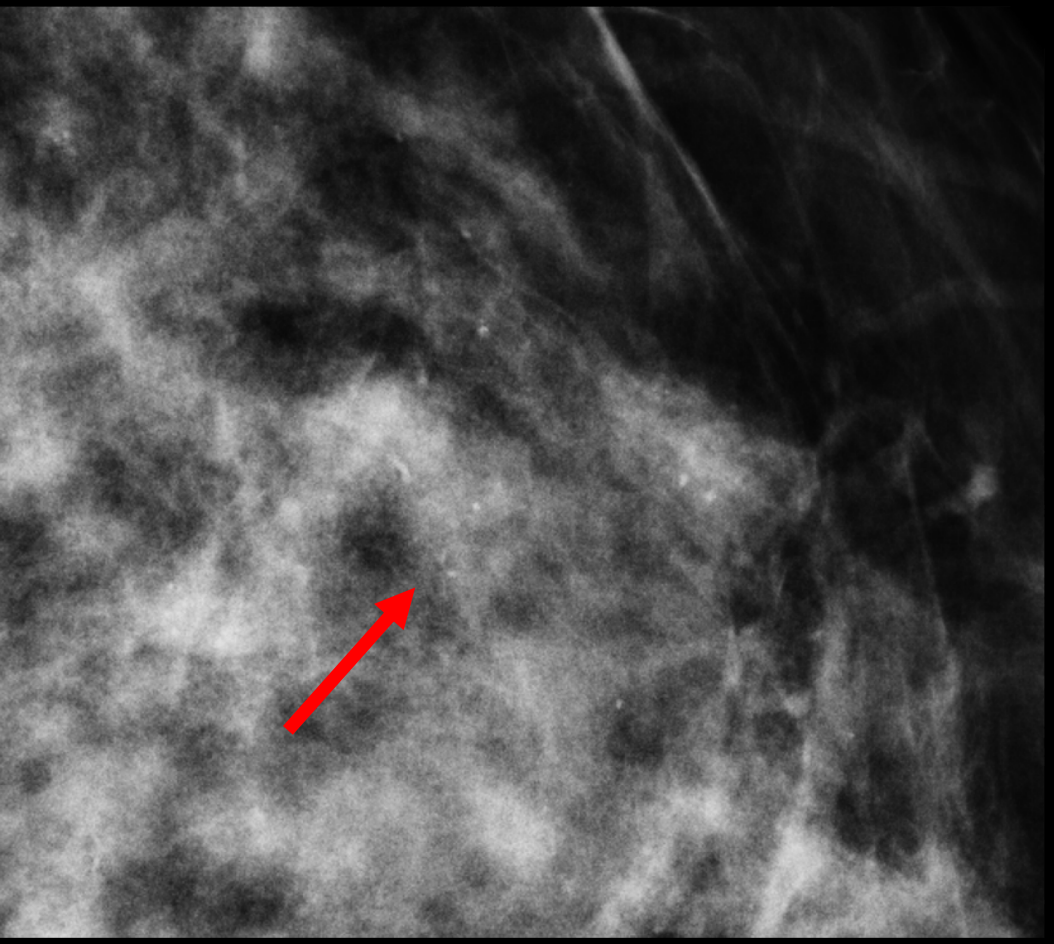

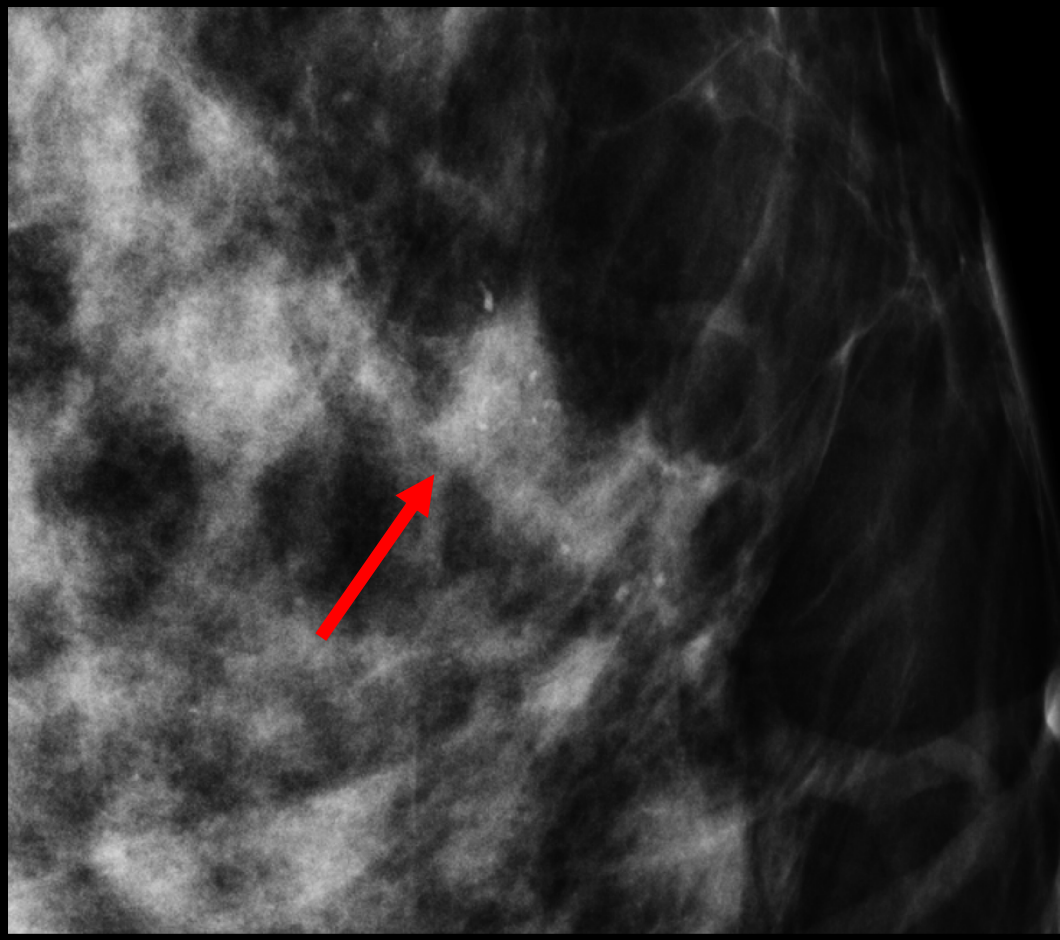

<u>Zoomed DM views</u>: Grouped calcifications, a few of which appear fine linear

Case 2: 44-yo for screening in combo DM/DBT mode

Left DBT slices:

Grouped calcifications in left upper outer quadrant

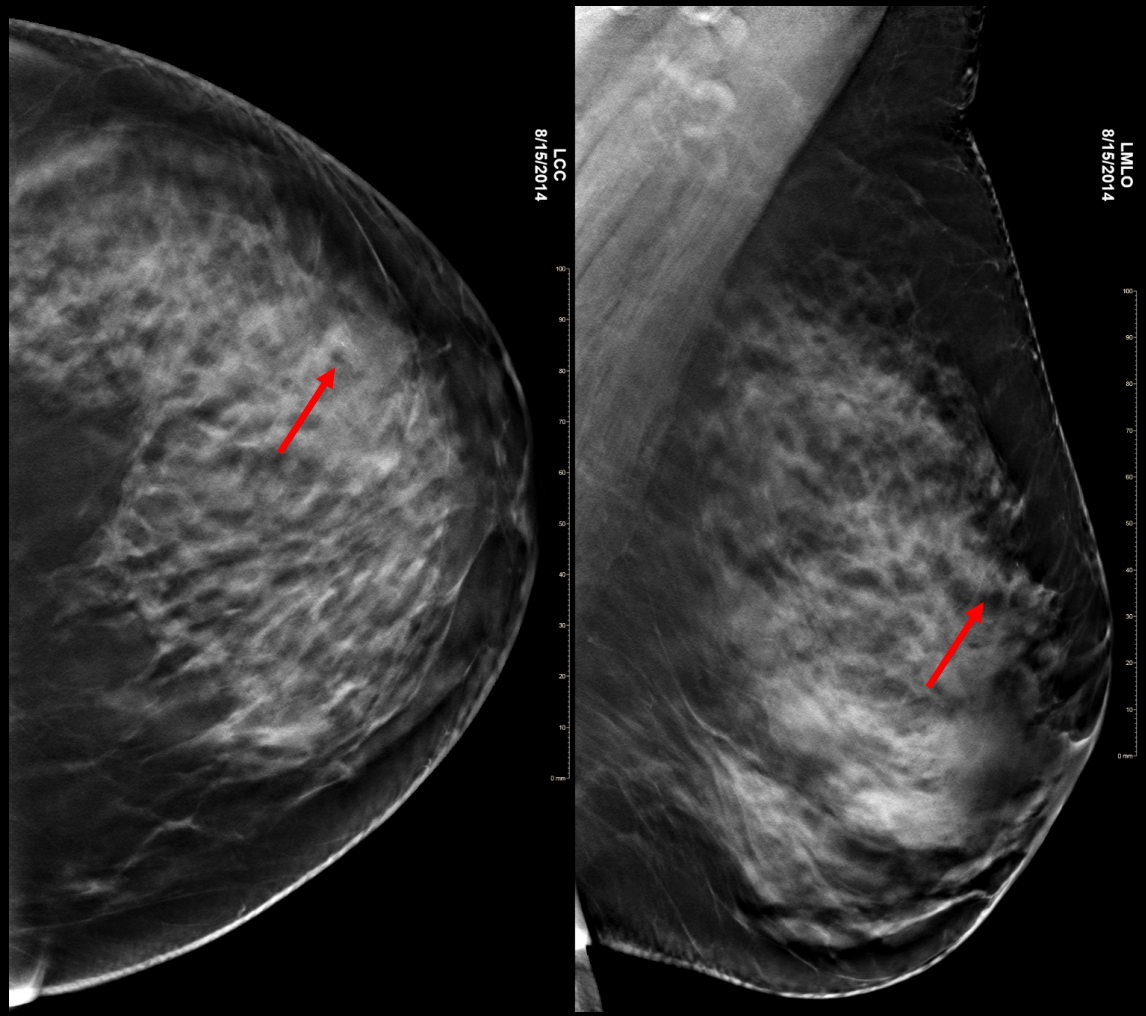

Case 2: Zoomed Lt DBT slices and histopathology

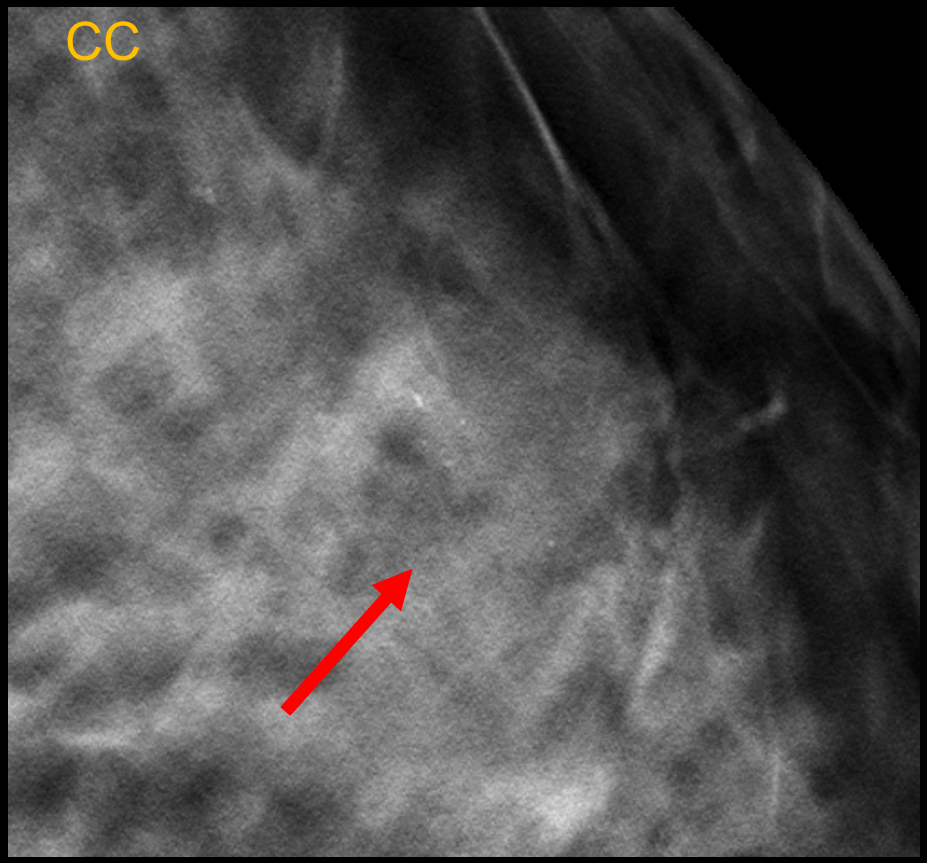

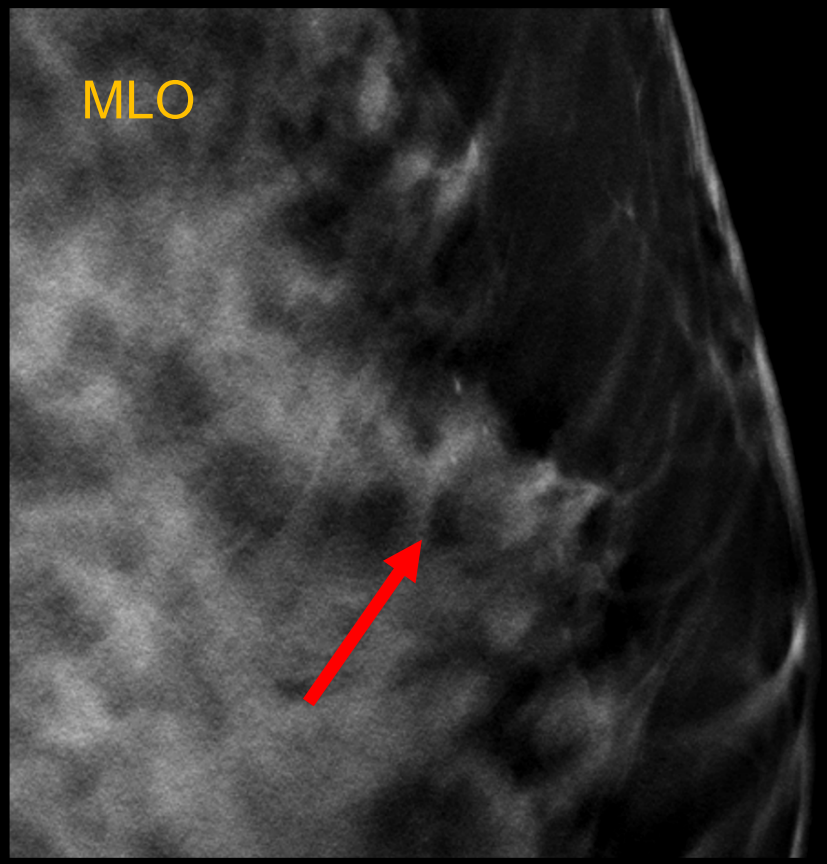

0.4-cm grade 3 DCIS

Case 2: Zoomed Lt DBT slices and histopathology

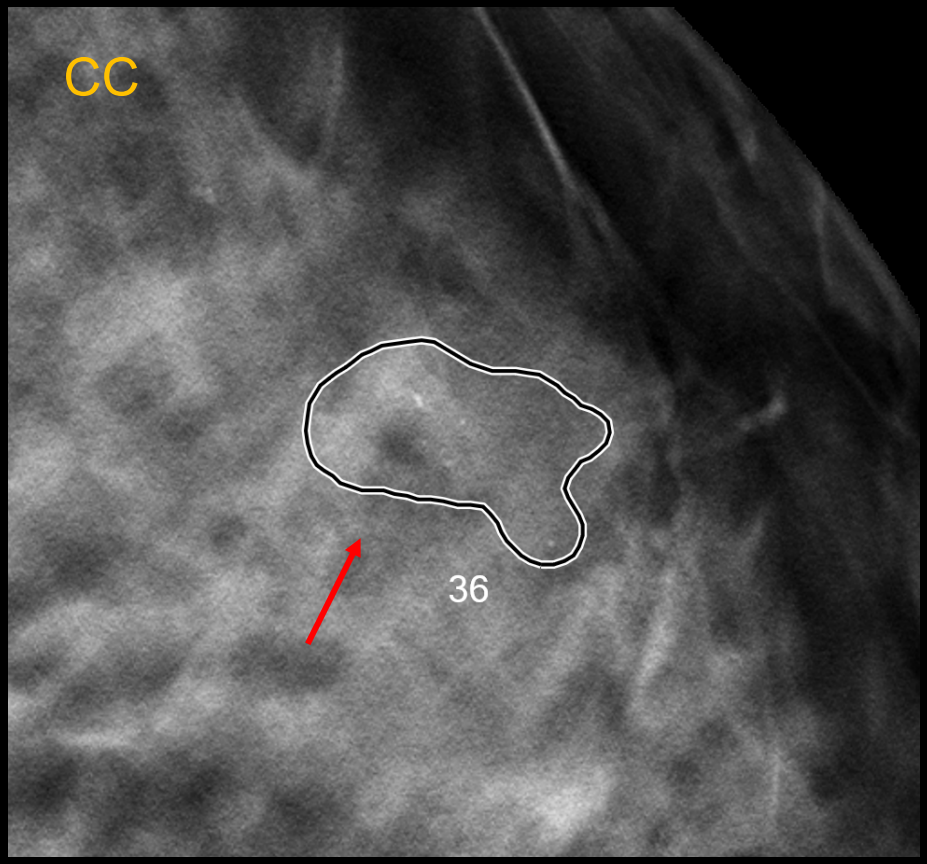

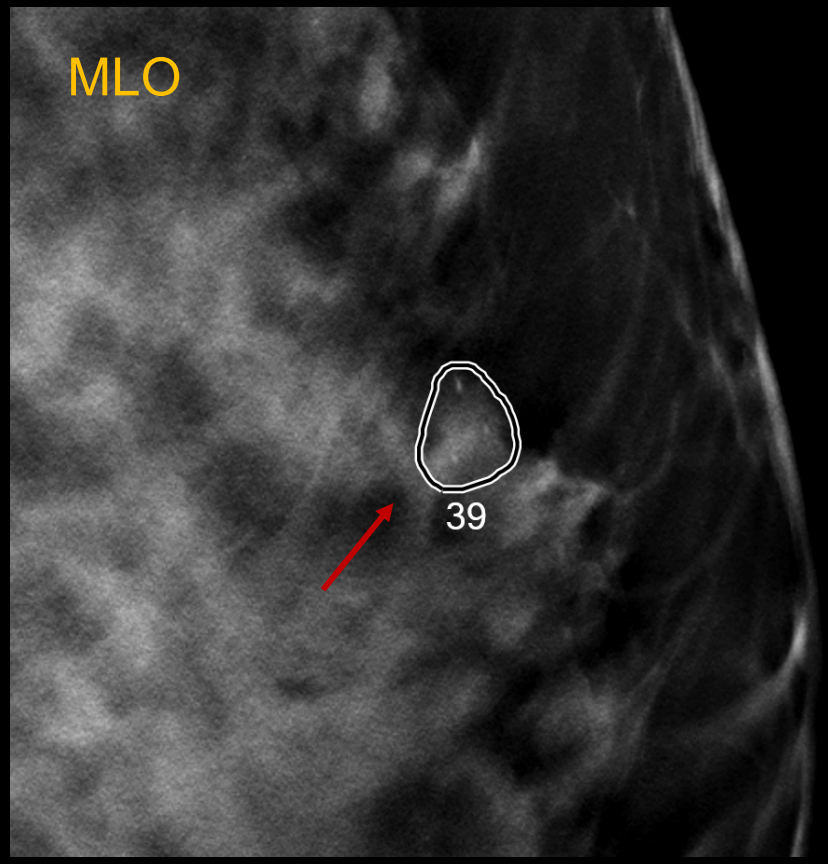

Case Score 51%

0.4-cm grade 3 DCIS

Case 2: Lt DBT slices with ProFound AI outlines and scores

Grouped calcifications in dense breasts detected by ProFound AI on both views

CC lesion score: 36%
MLO lesion score: 39%
Case score: 51%

without AI: 12 of 24 readers detected cancer
(average time*: 97.1 sec)

with AI: 21 of 24 (9 more**) readers detected cancer
(average time*: 51.0 sec)

Increased sensitivity with use of AI

* Average reading times are for all 24 readers
** 11 additional TPs minus 2 additional FNs with AI

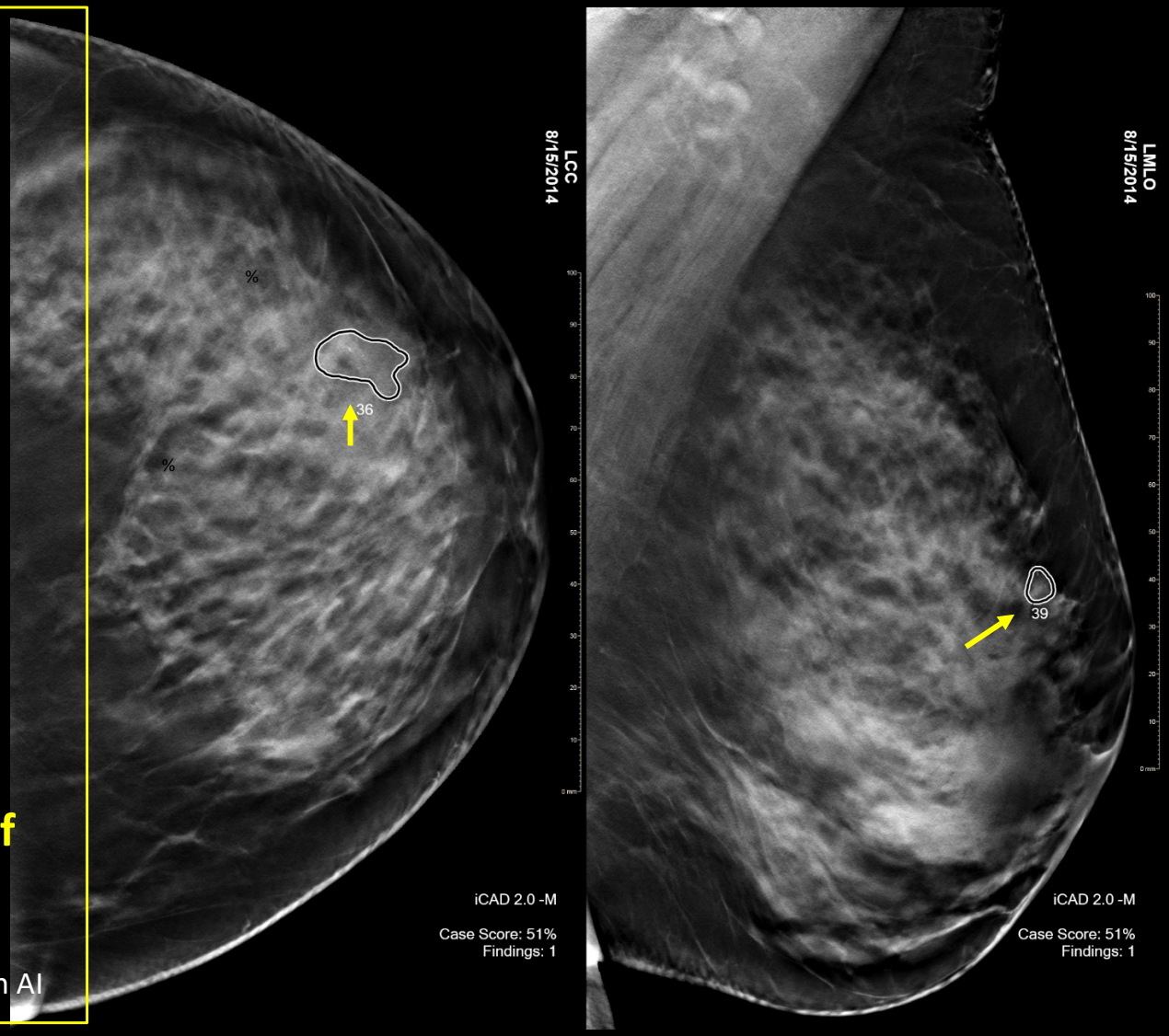

Accuracy of AI technology in breast imaging

- Conant, Hoffmeister et al. Radiology 2019 Jul 31 2019 https://doi.org/10.1148/ryai.2019180096
- Rodriguez Ruiz, et al Radiology 2019
- Rodriguez Ruiz et al J Natl Cancer 2019
- Wu et al IEEE Trans Med Imaging 2020
- McKinney et al. Nature Janurary 2020.

Figure 5. Example of a **receiver operating characteristic curve**. The green line represents a perfect classifier (with an AUC of 1), and the red line represents a random classifier (AUC of 0.5). Models with AUC above 0.5 (blue line) have some discrimination ability, with better models closer to 1.

sens

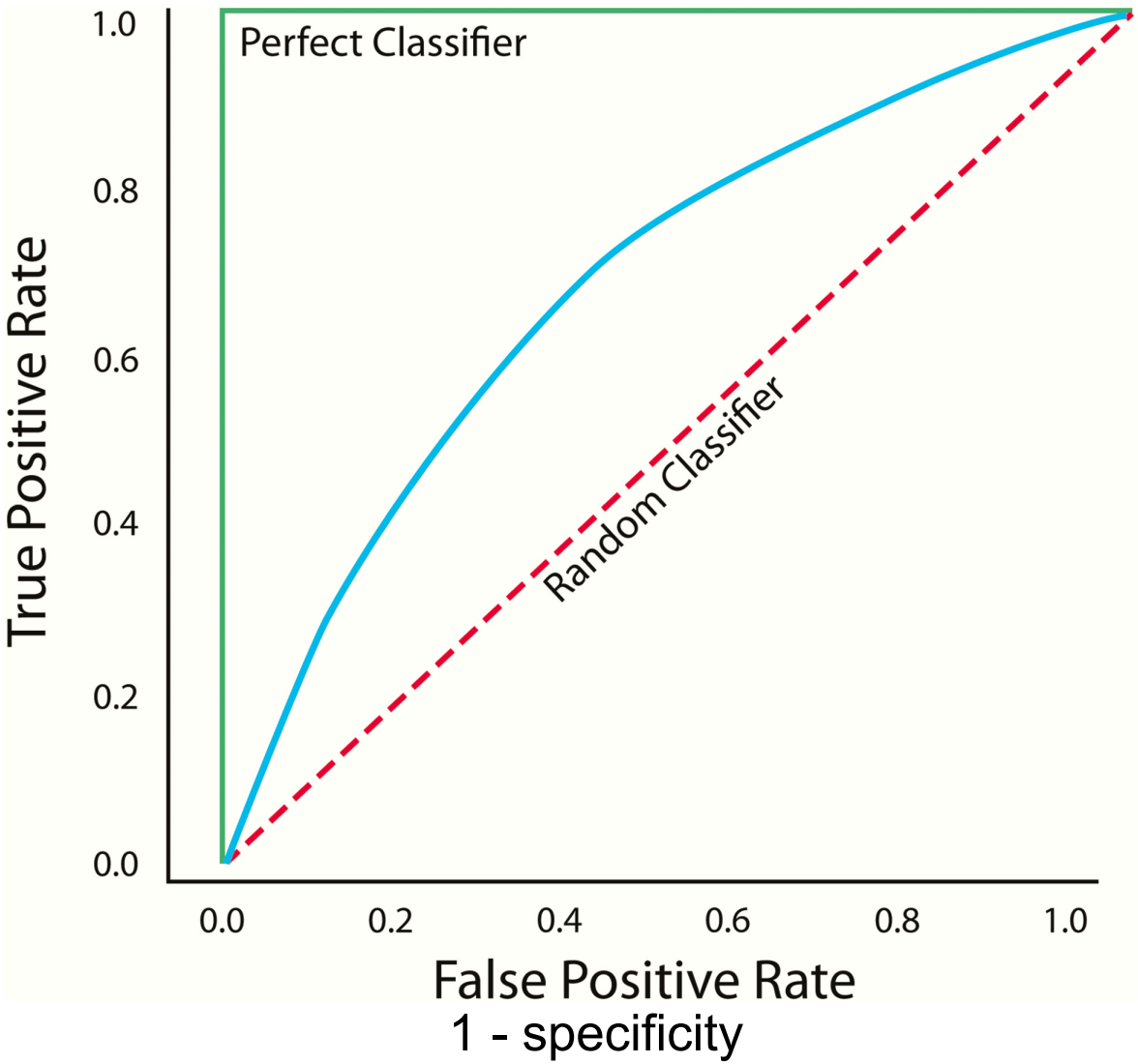

J Breast Imaging, Volume 2, Issue 4, July/August 2020, Pages 304–314,
https://doi.org/10.1093/jbi/wbaa033

Accuracy of AI technology in breast imaging

- Conant, Hoffmeister et al. Radiology 2019 Jul 31 2019 https://doi.org/10.1148/ryai.2019180096
- Rodriguez Ruiz, et al Radiology 2019
- Rodriguez Ruiz et al J Natl Canc 2019
- Wu et al IEEE Trans Med Imaging 2020
- McKinney et al. Nature January 2020.

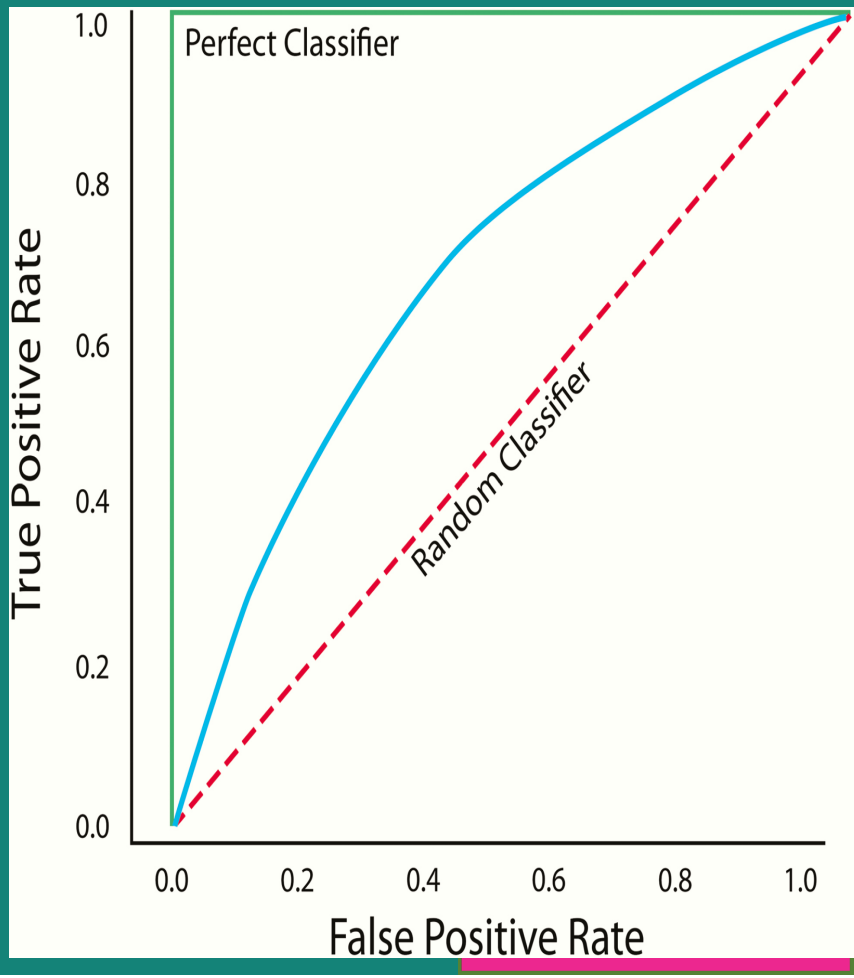

AI Patient risk stratification

- Density is a risk factor for breast cancer (D>A)
- Some risk assessment models (TC) incorporate breast density when evaluating risk
- With AI, image based models may offer more accurate risk prediction than density

AI and high risk lesions

- Current management of high risk lesions vary
- Papillomatosis, flat epithelial atypia
- AI can guide surveillance vs. surgical management

J Breast Imaging, Volume 2, Issue 4, July/August 2020, Pages 304–314, https://doi.org/10.1093/jbi/wbaa033

Artificial Intelligence in Breast Imaging

- Improved cancer detection
- Improved efficiency for the radiologist
- Clinical decision making for patients
  - Risk stratification for patients
  - Management of high risk lesions